

Mammographic density increase in women receiving different hormone replacement regimens[☆]

Cemal Tamer Erel^{a,*}, Gul Esen^b, Hakan Seyisoglu^a, Koray Elter^a, Cihan Uras^c, Erdogan Ertungealp^a, Mehmet Feridun Aksu^a

^a Department of Obstetrics and Gynecology, Cerrahpasa School of Medicine, Istanbul University, Istanbul, Turkey

^b Department of Radiology, Cerrahpasa School of Medicine, Istanbul University, Istanbul, Turkey

^c Department of Surgery, Cerrahpasa School of Medicine, Istanbul University, Istanbul, Turkey

Received 11 October 2000; received in revised form 8 May 2001; accepted 15 May 2001

Abstract

Objective: we investigated effects of different regimens of hormone replacement therapy (HRT) on mammographic density. **Methods:** ninety-five postmenopausal women, who were on different HRT regimens and completed their 4-year mammographic follow-up, were included into this retrospective and comparative study. Twenty-three of these women, who had surgical menopause, received conjugated equine estrogens (CEE) (Group I) only, 26 of them received CEE and continuous medroxyprogesterone acetate (MPA) (Group II), 21 women received CEE and cyclic MPA (Group III), and the remaining 25 women received tibolone (Group IV) therapy. Before commencing on HRT, a baseline high-resolution mammography was performed, and repeated at 6–12-month intervals during the period of 4-year follow-up. All mammographies were evaluated according to the Wolfe classification. **Results:** a diffuse increase in mammographic density was detected in five women (22%) in group I, nine women (35%) in group II, four women (19%) in group III, and two women (8%) in group IV. The increase in mammographic density was more common among women in group II than those in the other three groups. However, a statistically significant difference was found only between groups II and IV. **Conclusions:** different HRT regimens have different effects on breast parenchymal density on mammography. Continuous combination HRT may be more commonly associated with an increase in breast density than other forms of HRT. © 2001 Elsevier Science Ireland Ltd. All rights reserved.

Keywords: HRT; Mammography; Density; Breast

1. Introduction

Breast cancer is the most common gynecologic cancer among women. In a recent large re-analysis of epidemiological data, it has been claimed that current use of hormone replacement therapy (HRT) has caused a slight increase in the relative risk of breast cancer [1]. Although HRT for post-

[☆] Presented in 5th European Congress on Menopause, 1–5 July 2000, Copenhagen, Denmark.

* Corresponding author. Present address: Kasaneler Sk. Ni-garhanim Apt. No: 28/11 Erenkoy, 81070, Istanbul, Turkey. Tel.: +90-212-588-4800/1408; fax: +90-216-478-3899.

E-mail address: tamererel@superonline.com (C.T. Erel).

menopausal women improves quality of life by relieving menopausal symptoms and is thought to have beneficial effects on osteoporosis, coronary heart disease, and brain function in long-term, the relationship between HRT and breast cancer is the major reason for women not considering or discontinuing HRT.

Mammography is a non-invasive tool for early detection of breast cancer. Clinically significant mammographic findings for breast cancer are satellite lesions, circumscribed masses, microcalcifications, asymmetric densities and skin changes. It has been reported that the most common mammographic change in postmenopausal women receiving HRT is an increase in breast parenchymal density [2–12]. Density increase may obscure the other lesions of malignancy, and density increase itself may be one of the signs of malignancy. Earlier reports about mammographic changes after HRT have analyzed small groups of women and/or women who have been followed for short periods, or have analyzed different types of changes (microcalcification, masses, asymmetric densities) with incomplete information about the type of HRT regimens used or have used different types of estrogens and progestagens in the same group, i.e. study groups have not been homogeneous [2–12].

Currently, the three major HRT regimens (estrogen alone, estrogen in cyclic combination with a progestagen, and estrogen in continuous combination with a progestagen) are the most common ones used all over the world. Tibolone, which is a substance structurally related to 19-nortestosterone derivatives such as norethisterone and norethynodrel, is a drug used for HRT in Europe. It is a new synthetic steroid, designed to combine the favorable effects of estrogens, progestagens and androgens into a single substance [13]. In this retrospective study, we compared the effects of different HRT regimens on mammographic density during a 4-year follow-up period. To our best knowledge, this is the first study, which compares the rate of mammographic density increase during a 4-year follow-up period in different HRT groups, each of which is homogenous in terms of the type and dosage of HRT regimen.

2. Materials and methods

2.1. Subjects

Between January 1992 and August 1998, 95 postmenopausal women who were on different HRT regimens and had completed their 4-year mammographic follow-up, were included into this retrospective study. Postmenopausal status was defined as the presence of one of the following conditions: an age of at least 55 years without natural menses for at least 5 years; no natural menses for at least 1 year and a serum follicle-stimulating hormone (FSH) level of more than 40 IU/l; documented bilateral oophorectomy; or self-reported bilateral oophorectomy, an FSH level of more than 40 IU/l, and a serum estradiol level of less than 25 pg/ml. Of these 95 women, 23 have had surgical menopause, and received conjugated equine estrogens (CEE), 0.625 mg/day, only (Group I), 26 women received CEE, 0.625 mg/day, and continuous medroxyprogesterone acetate (MPA), 2.5 mg/day (Group II), 21 women received CEE, 0.625 mg/day for 28 days combined with cyclic MPA, 10 mg/day for the last 10 days (Group III), and the remaining 25 women received tibolone, 2.5 mg/day (Group IV). The women were followed annually. At baseline and annually thereafter, medical histories were taken, all the women underwent screening mammography and gynecologic examinations, including cervical smear, and their serum estradiol (E_2) levels were determined. Serum FSH and luteinizing hormone (LH) levels were determined at their initial visits and at the end of the fourth year of the treatment period.

Mean (\pm S.D.) age of the women was 50.14 ± 4.68 (range: 39–61 years) and mean (\pm S.D.) duration of menopause was 48.88 ± 33.08 months (range: 12–149 months) when the women started HRT. Breast tenderness was also inquired in their histories. Height and weight of the women were measured and their body mass indices (BMI) were determined. Mean (\pm S.D.) BMI was 27.32 ± 4.27 kg/m². Detailed explanation about HRT was given to women and their consents were taken.

2.2. Hormonal assays

Serum LH and FSH levels were measured by using a double antibody RIA technique (Diagnostic Products Corporation, Los Angeles, CA) and E_2 levels were measured by using the Coat-A-Count RIA kit (Diagnostic Products Corporation, Los Angeles, CA).

2.3. Radiologic evaluation

High-resolution mammography was performed prior to the start of HRT and was repeated at 6–12-month intervals according to the women's complaints, breast examination and earlier mammographic findings. All mammograms were obtained by using high-resolution film equipment (Siemens, Mammomat-3, Germany) at bilateral craniocaudal and mediolateral oblique positions and in lateral position if needed. Breast ultrasonography (Siemens, Sonoline SI-400, 7.5-MHz linear probe, Germany) was added to mammography as a complementary method for confirmation of any cystic lesion. The initial and last mammograms were interpreted by one expert radiologist (G.E.) in the Department of Radiology, who was blinded to the type of the HRT regimen, which the woman was on, and also, to the dates and order of mammograms. The radiologist reviewed all mammographies as to whether there was a subjective difference in density between mammographies and whether this was focal, multifocal or diffuse, and also evaluated the mammographies for presence of any mass and microcalcification. All mammograms were classified according to Wolfe classification [14,15]. This classification consists of: (1) N1, a breast composed mainly of fat; (2) P1, prominent ducts in the subareolar area involving only a small portion of the breast; (3) P2, more severe involvement with a prominent duct pattern; (4) DY, severe involvement with mammary dysplasia, with or without the presence of ducts. Change in parenchymal density was also evaluated according to the Wolfe's criteria; a focal increase in density was defined as a single area of increased mammographic density with no change in overall increase in density. A multifocal increase in density was defined as two or more

discrete areas of increased density without an increase in background density. Diffusely increased density was defined as an increase of more than 10% of breast volume in a continuous manner [14,15]. Rate of diffuse increase in breast density among women in the above groups were analyzed.

Statistical analysis of the data was performed by using one-way analysis of variance (ANOVA) and Fisher-exact tests where appropriate. *P* value of <0.05 was accepted as statistically significant.

3. Results

During the 4-year mammographic follow-up, a diffuse increase in mammographic density was detected in five women (21.74%) in group I, nine women (34.62%) in group II, four women (19.05%) in group III, and two women (8.00%) in group IV (Table 1 and Fig. 1). Although the increase in mammographic density seemed to be more common among women in group II than those in the other three groups, a statistically significant difference was found only between groups II and IV ($P = 0.019$).

Mean age, BMI, and baseline serum LH, FSH and E_2 levels were comparable between groups (Table 1). However, serum E_2 levels at the end of the 4-year follow-up were significantly lower in women receiving tibolone than those receiving one of the estrogen-based HRT regimens (Table 1).

4. Discussion

In the present study, four different HRT regimens had different effects on the parenchymal density of the postmenopausal breast. A diffuse increase in mammographic density was more common among postmenopausal women receiving continuous CEE-plus-MPA than those receiving tibolone. In this group, 35% of the women were found to have increased breast parenchymal density at the end of the 4-year follow-up period, and the corresponding figures for the CEE-plus-cyclic MPA, CEE-only, and tibolone groups were 22, 19, and 8%, respectively.

HRT may reduce the sensitivity of mammography and hamper the detection of breast cancer by obscuring a small malignant mass, which does not cause a distortion of the surrounding tissue [16,17]. In addition, mammographic density increase per se may be one of the signs of malignancy. High-density mammographic pattern is an independent risk factor for breast cancer [18]. Therefore, we specifically analyzed the mammographic density increase as well as the other mammographic changes in this study.

Our results are in agreement with some earlier reports about the association between the mammographic density increase and combined HRT regimens [2,7,8,12]. There is a debate on which regimen (cyclic versus continuous, including the type of estrogen and progesterone used in these regimens) is more likely to increase the breast density. Although, we observed that increase in breast density was more common with continuous combined CEE-plus-MPA regimen (35%) than cyclic combination (22%), the difference was not statistically significant. In a recent report, it has been claimed that an increase in mammographic density is much more common among women receiving estrogen-plus-continuous progesterone than those receiving estrogen-plus-cyclic proges-

terone (52 vs. 13%) [12]. However, in that study, two different types of cyclic HRT regimens were given to the women in the same group. Most of the studies regarding the mammographic density change in women on HRT have included various forms of estrogen and progesterone in the same treatment group or even the types of estrogen and progesterone have not been specified [2,7–9,12]. In our study, only one type of estrogen and progesterone (CEE and MPA) were used. Two recent reports have announced that combined estrogen and progesterone therapy markedly enhances the risk of breast cancer relative to estrogen use alone [19,20]. Therefore, if an estrogen-based HRT regimen is prescribed for a woman, a cyclic regimen may be preferable in selected patients, who have a high breast cancer risk.

Mammographic density changes in women with increasing age. Fat tissue replaces breast tissue with increasing age and the mammographic change in density with aging is from a denser breast parenchyma in younger women towards a lesser dense parenchyma in older women [14]. In our earlier report, we pointed out the association between serum E₂ levels and mammographic density changes in women receiving HRT [5]. Many

Table 1

Age, BMI, serum hormone levels, and rate of parenchymal density increase on mammography in women receiving four different HRT regimens

	Group I (CEE alone, <i>n</i> = 23)	Group II (CEE + co. MPA, <i>n</i> = 26)	Group III (CEE + cy. MPA, <i>n</i> = 21)	Group IV (Tibolone, <i>n</i> = 25)	<i>P</i>
Age (years)	48.70 ± 3.08	50.73 ± 5.50	50.14 ± 4.96	50.84 ± 4.72	NS
BMI (kg/m ²)	27.95 ± 5.09	26.06 ± 3.99	27.88 ± 4.63	27.64 ± 3.36	NS
Duration of menopause (mo)	54.17 ± 37.68	47.23 ± 41.21	51.14 ± 23.32	43.64 ± 26.46	NS
FSH (IU/ml)	48.39 ± 19.88	55.11 ± 24.39	47.73 ± 24.96	61.45 ± 22.03	NS
LH (IU/ml)	45.79 ± 20.40	51.56 ± 18.93	41.13 ± 12.60	41.05 ± 14.79	NS
Initial estradiol (pg/ml)	15.71 ± 10.89	19.65 ± 18.10	24.56 ± 25.55	27.02 ± 18.58	NS
Last estradiol (pg/ml)	144.79 ± 65.43	133.17 ± 49.21	144.08 ± 88.64	14.99 ± 11.39	<0.001 ^a
Women with density (<i>n</i> (%))	5 (21.74)	9 (34.62)	4 (19.05)	2 (8.00)	0.019 ^b

Values are expressed as mean ± S.D., and mo, month; co, continuous; cy, cyclic.

^a This is the *P* value for the differences between group IV and each of the other estrogen-based HRT regimens.

^b This is the *P* value for the difference between groups II and IV.

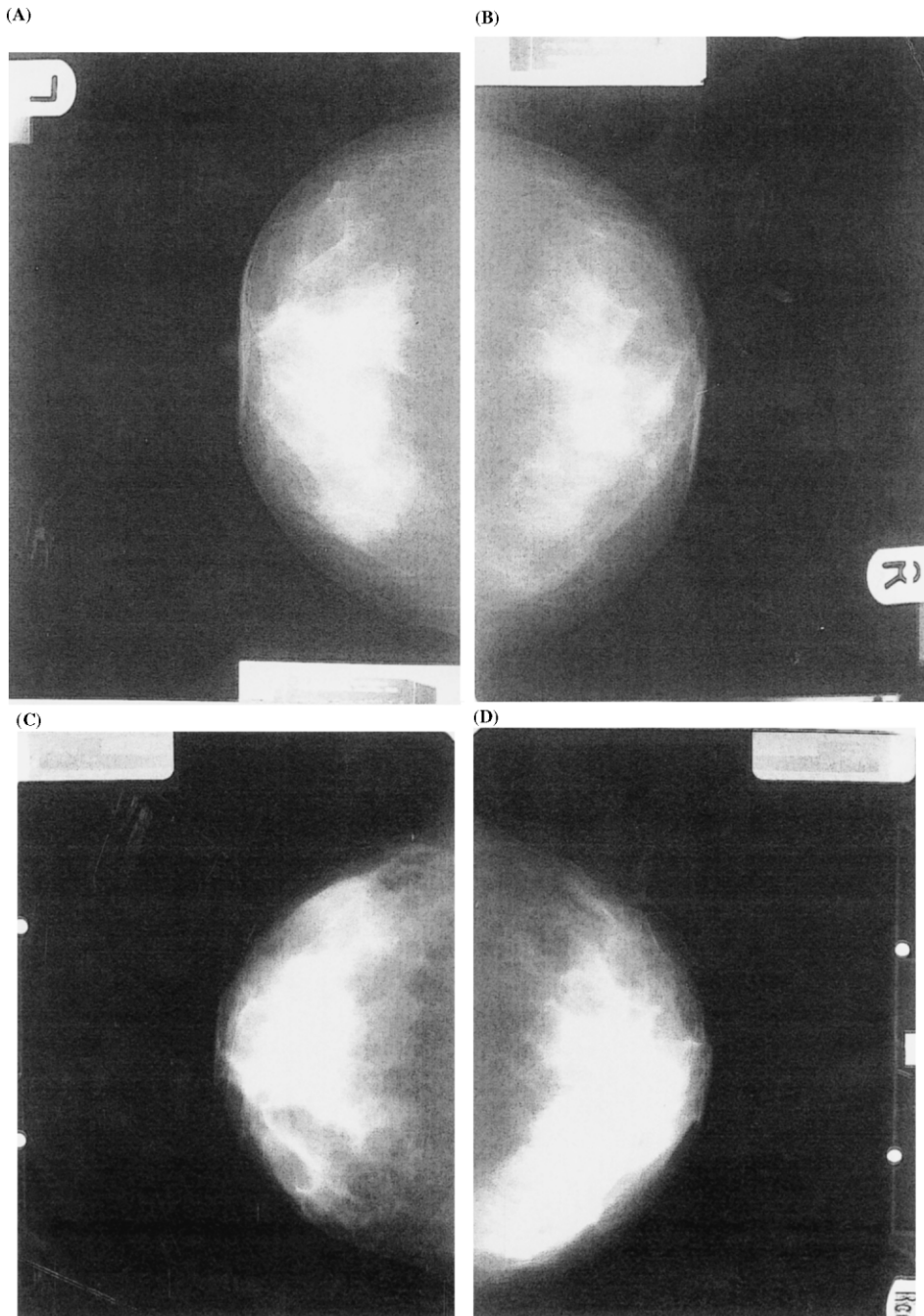


Fig. 1. Mammographic density increase in a woman receiving HRT during the 4-year follow-up. (A) Initial left craniocaudal, (B) initial right craniocaudal, (C) last left craniocaudal, (D) last right craniocaudal mammographies.

authors have been in agreement with proliferative effects of E_2 on breast parenchyma [21]. On the other hand, in menstruating women, breast epithelial proliferation is increased during the luteal phase, when endogenous progesterone levels are high [22]. A positive correlation between breast epithelial proliferation and serum progesterone levels has been reported [22]. In adult ovariectomized cynomolgus macaques, estrogen-plus-progesterone induces greater breast epithelial cell proliferation than estrogen alone [23]. Recently, it has been shown that HRT with CEE-plus-MPA causes a significantly higher breast epithelial proliferation than estrogen alone in normal postmenopausal women [24]. Recent evidence has supported the idea that addition of progesterone to HRT enhances the risk of breast cancer relative to estrogen use alone [19,20]. However, effects of progesterone on mammographic density increase should be investigated according to the type, dosage, duration of exposure, and type of HRT regimen, i.e. cyclic versus continuous administration.

In this study, we reported parenchymal density increase in only 8% of women receiving tibolone. It was observed to be least likely to cause an increase in breast density when compared with other HRT regimens. Effect of tibolone on mammographic density increase is under current investigation. Our earlier report has heralded a microcalcification in a woman and density increase in another woman receiving tibolone therapy as mammographic changes at the end of the 24-month follow-up [6]. Subsequently, two reports have reported similar results and suggested the less frequent density increase in women on tibolone than those on estrogen-plus-progesterone [10,11]. In one of those studies, which is a prospectively randomized one, it has been shown that estrogen-plus-progesterone therapy is associated with an increase in mammographic density and claimed that tibolone does not seem to affect breast structure [11]. There are no human studies that have analyzed the association between breast cancer risk and tibolone. However, tissue studies have demonstrated that tibolone markedly inhibits breast cell proliferation in both human and animal [25,26].

In conclusion, different HRT regimens may cause different rates of mammographic density

increase. This controlled, retrospective study shows that tibolone causes lesser changes in breast parenchymal density than estrogen-based HRT regimens. In this study, we confirmed our earlier results for a longer duration of treatment and in a controlled design. Therefore, we strongly believe that tibolone is a safe alternative for women who have a high risk of breast cancer. In addition, we observed that when estrogen-based HRT regimen is considered for non-hysterectomized women, cyclic combination of a progestagen might be more advantageous than a continuous combination, since it is less likely to cause an increase in breast density.

References

- [1] Collaborative Group on Hormonal Factors in Breast Cancer. Breast cancer and hormone replacement therapy: collaborative reanalysis of data from 51 epidemiological studies of 52 705 women with breast cancer and 108 411 women without breast cancer. *Lancet* 1997; 350: 1047–59.
- [2] Stomper PC, Van Voorhis BJ, Ravnikar VA, Meyer JE. Mammographic changes associated with postmenopausal hormone replacement therapy: a longitudinal study. *Radiology* 1990;174:487–90.
- [3] Berkowitz JE, Gatewood OM, Goldblum LE, Gayler BW. Hormonal replacement therapy: mammographic manifestations. *Radiology* 1990;174:199–201.
- [4] Laya MB, Gallagher JC, Schreiman JS, Larson EB, Watson P, Weinstein L. Effect of postmenopausal hormonal replacement therapy on mammographic density and parenchymal pattern. *Radiology* 1995;196:433–7.
- [5] Erel CT, Seyisoglu H, Senturk ML, Akman C, Ersavasti G, Benian A, Uras C, Altug A, Ertungealp E. Mammographic changes in women on hormonal replacement therapy. *Maturitas* 1996;25:51–7.
- [6] Erel CT, Elter K, Akman C, Ersavasti G, Altug A, Seyisoglu H, Ertungealp E. Mammographic changes in women receiving tibolone therapy. *Fertil Steril* 1998;69:870–5.
- [7] Persson I, Thurffjell E, Holmberg L. Effect of estrogen and estrogen-progestin replacement regimens on mammographic breast parenchymal density. *J Clin Oncol* 1997;15:3201–7.
- [8] Marugg RC, van der Mooren MJ, Hendriks JH, Rolland R, Ruijs SH. Mammographic changes in postmenopausal women on hormonal replacement therapy. *Eur Radiol* 1997;7:749–55.
- [9] Leung W, Goldberg F, Zee B, Sterns E. Mammographic density in women on postmenopausal hormone replacement therapy. *Surgery* 1997;122:669–73.
- [10] Colacurci N, Mele D, De Francis P, Costa V, Fortunato N, De Seta L. Effects of tibolone on the breast. *Eur J Obstet Gynecol Reprod Biol* 1998;80:235–8.

- [11] Ozdemir A, Konus O, Nas T, Erbas G, Cosar S, Isik S. Mammographic and ultrasonographic study of changes in the breast related to HRT. *Int J Gynaecol Obstet* 1999;67:23–32.
- [12] Lundstrom E, Wilczek B, von Palffy Z, Soderqvist G, von Schoultz B. Mammographic breast density during hormone replacement therapy: differences according to treatment. *Am J Obstet Gynecol* 1999;181:348–52.
- [13] Moore RA. Livial: a review of clinical studies. *Br J Obstet Gynaecol* 1999;106(Suppl.19):1–21.
- [14] Wolfe JN. Breast parenchymal patterns and their changes with age. *Radiology* 1976;121:545–52.
- [15] Wolfe JN. Breast patterns as an index of risk for developing breast cancer. *Am J Radiol* 1976;126:1130–9.
- [16] Kavanagh AM, Mitchell H, Giles GG. Hormone replacement therapy and accuracy of mammographic screening. *Lancet* 2000;355:270–4.
- [17] Laya MB, Larson EB, Taplin SH, White E. Effect of estrogen replacement therapy on the specificity and sensitivity of screening mammography. *J Natl Cancer Inst* 1996;88:643–9.
- [18] Hill P. Breast density and cancer. *J Natl Cancer Inst* 1997;89:1721–2.
- [19] Magnusson C, Baron JA, Correia N, Bergstrom R, Adami HO, Persson I. Breast-cancer risk following long-term oestrogen- and oestrogen-progestin-replacement therapy. *Int J Cancer* 1999;81:339–44.
- [20] Ross RK, Paganini-Hill A, Wan PC, Pike MC. Effect of hormone replacement therapy on breast cancer risk: estrogen versus estrogen plus progestin. *J Natl Cancer Inst* 2000;92:21.
- [21] Santen RJ, Yue W, Naftolin F, Mor G, Berstein L. The potential of aromatase inhibitors in breast cancer prevention. *Endocr Relat Cancer* 1999;6:235–43.
- [22] Soderqvist G, Isaksson E, von Schoultz B, Carlstrom K, Tani E, Skoog L. Proliferation of breast epithelial cells in healthy women during the menstrual cycle. *Am J Obstet Gynecol* 1997;176:123–8.
- [23] Cline JM, Soderqvist G, von Schoultz E, Skoog L, von Schoultz B. Effects of hormone replacement therapy on the mammary gland of surgically postmenopausal cynomolgus macaques. *Am J Obstet Gynecol* 1996;174:93–100.
- [24] Hofseth LJ, Raafat AM, Osuch JR, Pathak DR, Slomski CA, Haslam SZ. Hormone replacement therapy with estrogen or estrogen plus medroxyprogesterone acetate is associated with increased epithelial proliferation in the normal postmenopausal breast. *J Clin Endocrinol Metab* 1999;84:4559–65.
- [25] Kloosterboer HJ, Schoonen WG, Deckers GH, Klijn JG. Effects of progestagens and OrgOD14 in in-vitro and in-vivo tumor models. *J Steroid Biochem Mol Biol* 1994;49:311–8.
- [26] Kandouz M, Lombet A, Perrot JY, Jacob D, Carvajal S, Kazem A, Rostene W, Therwath A, Gompel A. Proapoptotic effects of antiestrogens, progestins and androgen in breast cancer cells. *J Steroid Biochem Mol Biol* 1999;69:463–71.