

## Case Report

# Successful Medical Management of Post-hysteroscopic Metroplasty Bleeding with Intravenous Estrogen Therapy: A Report of Two Cases and Review of the Literature

Bert Scoccia, MD\*, Habibe Demir, MD, Koray Elter, MD, and Antonio Scommegna, MD

*Division of Reproductive Endocrinology and Infertility, Department of Obstetrics and Gynecology, University of Illinois College of Medicine, Chicago, Illinois (all authors).*

---

**ABSTRACT** Complications from hysteroscopy are rare, but some are potentially life-threatening. Hemorrhage is one of the most common complications of hysteroscopy. In this study, we report 2 cases of post-hysteroscopic bleeding successfully treated with intravenous conjugated equine estrogen (CEE). In our case report, 2 women who were evaluated for infertility were diagnosed with intrauterine septum. After surgical resection of the septum, significant late post-hysteroscopic bleeding was seen in the fourth and eighteenth day of surgery, respectively. Both patients were successfully treated with intravenous CEE 25 mg in normal saline solution 50 mL given over 20 minutes every 6 hours. These 2 cases illustrate that intravenous CEE therapy as a short-term treatment is relatively safe and can be considered as an alternative in the treatment of severe post-hysteroscopy bleeding in selected patients without risk factors. In patients with risk factors, such as previous thromboembolic disease, alternative modalities of treatment should be considered. *Journal of Minimally Invasive Gynecology* (2009) 16, 639–42 © 2009 AAGL. All rights reserved.

**Keywords:** Intravenous; Conjugated equine estrogen; Premarin; Hysteroscopy; Complications; Bleeding

---

Complications from hysteroscopy are relatively rare events. However, as the use of hysteroscopy increases as a surgical alternative for various gynecologic problems, the importance of managing these complications rises. In a multicenter study from Germany, complications were seen in 0.22% of all 21 676 evaluated hysteroscopies [1]. Jansen et al. [2] have reported complication rates of 0.13% with diagnostic procedures and 0.95% with operative procedures among 13 600 procedures at a multicenter study.

Propst et al. [3] noted that complications are directly proportional to the type of hysteroscopic procedure performed. Operative procedures associated with the highest complication rates included myomectomy and resection of

uterine septa, whereas polypectomies and endometrial ablations had the lowest rates of complications. After intravasation of distention fluid and uterine perforation, hemorrhage is one of the most common complications of hysteroscopy [4]. Because the intrauterine instillation fluid pressure is decreased at the end of the procedure, postoperative bleeding is much more common than intraoperative bleeding. Second-look operative hysteroscopy with the use of electrosurgery to stop bleeding has been reported [5]. Alternatively, intrauterine insertion of a Foley balloon, filling the uterus with vasopressin-soaked packing, intracervical injection of vasopressin, bilateral uterine artery embolization or ligation, and emergency hysterectomy, as the last choice, are the modalities of treatment for post-hysteroscopy bleeding [6, 7].

Parenteral administration of conjugated equine estrogens (CEE) is widely used for dysfunctional uterine bleeding [8]. This approach seems to be effective. However, the mechanism of action is unclear and may not be specific to the endometrium itself, because similar approaches have been reported successfully in the hematology, gastrointestinal, and otolaryngology literature [8,9]. These observations prompted us to use intravenous CEE for post-hysteroscopy bleeding. On the basis of our literature search from 1966 to

---

The authors have no commercial, proprietary, or financial interest in the products or companies described in this article.

Corresponding author: Bert Scoccia, MD, Division of Reproductive Endocrinology and Infertility, Department of Obstetrics and Gynecology (MC 808), University of Illinois College of Medicine, 820 South Wood St, Chicago, IL 60612-7313.  
E-mail: bscocc@uic.edu

Submitted February 20, 2009. Accepted for publication May 21, 2009.  
Available at [www.sciencedirect.com](http://www.sciencedirect.com) and [www.jmig.org](http://www.jmig.org)

the present, using the keywords “Premarin,” “conjugated estrogens,” “hysteroscopy,” “bleeding,” we report the first 2 cases of post-hysteroscopy bleeding treated successfully with intravenous CEE.

### Case 1

A 31-year-old woman, gravida 2 aborta 2, presented with a history of first trimester spontaneous abortions and 2 years of secondary infertility. She had a history of regular menstrual cycles. An infertility evaluation including semen analysis and basal body temperature charts revealed normal findings. Hysterosalpingography revealed 2 cavities with a clear central division, suggesting a septate versus a bicornuate uterus. The result of intravenous pyelography was normal.

After discussing her previous spontaneous abortion history, the patient consented to diagnostic laparoscopy and operative hysteroscopy. No preoperative or immediate postoperative medical suppression was used. Laparoscopy revealed stage I endometriosis. The uterine external surface was normal in shape and size; however, several small subserosal fibroids were noted. An extensive uterine septum extending down to 80% of the uterine cavity was noted. Two separate operative hysteroscopic procedures, 3 months apart, in the proliferative phase of the menstrual cycle were required because of the extensive septum, as well as difficulty with visualization during the first procedure. An operative hysteroscope (Storz, Tuttlingen, Germany) with 3-mm scissors was used during both procedures, under laparoscopic control. At the time of the second operative hysteroscopy the patient had no bleeding both during and after surgery, and she was discharged on the same day.

On the fourth postoperative day, she was seen in the emergency department because of the sudden onset of severe vaginal hemorrhage. On admission, the patient was noted to have significant vaginal bleeding with clotting, a pulse rate of 120 beats/min and a blood pressure of 140/60 mm Hg, and her initial hemoglobin was 12.1 mg/dL. Therapy was commenced with intravenous CEE 25 mg (Premarin; Wyeth-Ayerst Laboratories, Philadelphia, PA) in normal saline solution 50 mL given over 20 minutes. She had a quick response to intravenous CEE infusion, with complete arrest of bleeding. Her hemoglobin was 8 mg/dL the next day and 7.5 mg/dL on the second day. The patient was started on iron supplementation and had no further vaginal bleeding. The patient was free of any severe symptoms other than occasional dizziness with prolonged ambulation and was discharged on the second day. The patient was sent home on estrogen supplementation for 4 weeks after surgery, plus progesterone supplementation during the last 10 days, to prevent further bleeding for 1 month after discharge from the hospital.

### Case 2

A 28-year-old woman, gravida 0, presented with a history of regular menstrual cycles, chronic pelvic pain, and

infertility, and she was status post prior longitudinal vaginal septum excision. She also had been placed on low-dose oral contraceptives for 2 months for a persistent left ovarian cyst and her oral contraceptives were stopped the day before surgery. On examination, the patient was noted to have a double cervix and a left ovarian cystic mass. Ultrasound examination revealed a simple cyst, 60 × 50 mm in size in the left ovary. On hysterosalpingography 2 separate cervical openings were cannulated, and contrast was injected. Findings were consistent with didelphic versus a septate uterus with cervical duplication. The result of intravenous pyelography was normal.

We discussed with this patient the prognosis for future pregnancies with a septate uterus [10-12] and the reported cumulative pregnancy rates after septum excision in infertile women without prior spontaneous abortions [11,13,14]. After informed consent was obtained, a combined operative laparoscopy and hysteroscopy were done. The left ovarian cyst was excised, and minimal endometriosis was noted. The uterine fundus contour was normal, and these findings confirmed a complete septate uterus with cervical duplication [15,16]. During hysteroscopy, a complete uterine septum was excised up to the level of the endocervix, under laparoscopic control with an operating hysteroscope with 3-mm scissors (Storz, Tuttlingen, Germany). The procedure was uneventful with minimal bleeding both during surgery and in the recovery room. The patient was discharged on the same day. Eighteen days after surgery the patient presented to the emergency department with severe vaginal hemorrhage. Her admitting hemoglobin was 11 mg/dL. The patient required 2 doses of intravenous CEE 25 mg in normal saline solution 50 mL given over 20 minutes 6 hours apart. Her bleeding stopped completely, and her hemoglobin had decreased to 8 mg/dL. She was discharged the following day on estrogen supplementation for 4 weeks, with the addition of progestin during the last 10 days, to suppress any further bleeding for 1 month after discharge from the hospital.

### Discussion

Our 2 cases are of interest because of the significant delay in postoperative bleeding and the ability to arrest the hemorrhage with intravenous CEE, thus avoiding the need for repeat surgery. To our knowledge, only Kazer et al [5] reported 2 cases of late hemorrhage after hysteroscopy. Their patients complained of heavy vaginal bleeding 5 and 7 days after surgery, and both required repeat surgery to arrest the bleeding.

In a double-blind, placebo-controlled study, DeVore et al [17] studied 34 women with excessive or prolonged menorrhagia. Eighteen of these women were treated with intravenous CEE, and 16 of them with placebo. There was a significant decrease in blood loss with intravenous CEE versus placebo. The change from the baseline injection of intravenous CEE or placebo for blood pressure, and pulse was not statistically significant. The adverse effects reported

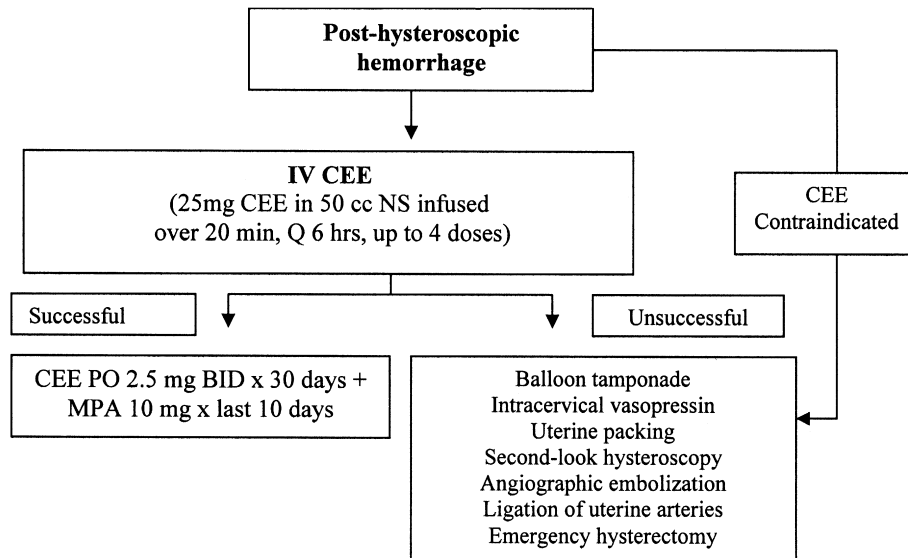


Fig. 1. Suggested scheme for post-hysteroscopic hemorrhage. IV = intravenous; PO = by mouth; BID = twice daily; MPA = medroxyprogesterone acetate.

in that study included nausea, flushing, drowsiness, and dizziness.

A theoretic risk of thromboembolic complications has been inferred on the basis of previous studies of oral contraceptives and estrogen replacement therapy. However, only 1 case has been reported with use of intravenous CEE therapy [18]. In that case, the patient was treated with intravenous CEE for severe menorrhagia, and she was also taking GnRH agonist treatment combined with add-back therapy consisting of 0.625 mg of CEE plus medroxyprogesterone acetate 10 mg for uterine fibroids. This might have contributed to the development of that thromboembolic event.

Conjugated estrogens have been reported to correct prolonged bleeding times and improve the primary hemostatic process in patients with several types of bleeding problems [8,9]. They appear to be effective in patients with kidney failure and in patients with advanced liver sclerosis who have hematologic abnormalities [19]. They also appear to be effective in uncontrolled hemorrhage caused by duodenal ulcers, subarachnoid hemorrhage, and rectal hemorrhages in patients with no hematologic abnormalities [19]. Prospective studies with the preoperative administration of CEE have shown decreased intraoperative blood loss, especially in cardiovascular and ophthalmologic surgery [19]. In another prospective study Frenette et al [20] reported that patients treated with conjugated estrogen received less fresh-frozen plasma, red blood cells, and platelets during orthotopic liver transplantation.

The pharmacologic mechanism of the hemostatic action of CEE remains obscure. Coagulation and fibrinolysis studies have demonstrated that conjugated estrogens are associated with (1) increased fibrinogen levels within 6 hours of administration; (2) increased factors V and IX; (3) platelet aggregation; (4) interference with tissue reactions to bradykinin; (5) increased mucopolysaccharide content of connective tissue

ground substance; (6) decreased capillary permeability [17]; (7) increased plasma levels of von Willebrand factor antigen [21]; and (8) increased platelet reactivity, as indicated by an increased of thromboxane A<sub>2</sub> and  $\beta$ -thromboglobulin concentration in the microvasculature [22]. All these effects, acting either separately or together, can result in capillary hemostasis and rapid cessation of small-vessel bleeding.

Most authors agree that conjugated estrogens act on the capillary apparatus chiefly by inducing polymerization in the walls of the capillaries and arterioles [19]. Estrogens change acid mucopolysaccharides from the solid state to the gel state, and as a result, the vessel walls become less permeable [19]. Evidence of a receptor mechanism for the action of estrogen comes from the fact that specific estrogen receptor antagonists, including tamoxifen and clomiphene citrate, prevent the shortening of the bleeding time induced by estrogens in uremia [9].

We conclude that intravenous CEE therapy as a short-term treatment is relatively safe and can be considered as an alternative in the treatment of severe post-hysteroscopy bleeding in selected patients without risk factors (Fig. 1). In patients with risk factors, such as previous thromboembolic disease, alternative modalities of treatment should be considered.

## References

1. Aydeniz B, Gruber IV, Schauf B, et al. A multicenter survey of complications associated with 21,676 operative hysteroscopies. *Eur J Obstet Gynecol Reprod Biol.* 2002;104:160–164.
2. Jansen FW, Vredevoogd CB, van Ulzen K, et al. Complications of hysteroscopy: a prospective, multicenter study. *Obstet Gynecol.* 2000;96:266–270.
3. Propst AM, Liberman RF, Harlow BL, et al. Complications of hysteroscopic surgery: predicting patients at risk. *Obstet Gynecol.* 2000;96:517–520.

4. Jansen FW, van Dongen H. [Hysteroscopy: useful in diagnosis and surgical treatment of intrauterine lesions]. *Ned Tijdschr Geneesk.* 2008;152:1961–1966.
5. Kazer RR, Meyer K, Valle RF. Late hemorrhage after transcervical division of a uterine septum: a report of two cases. *Fertil Steril.* 1992; 57:930–932.
6. Isaacson KB. Complications of hysteroscopy. *Obstet Gynecol Clin North Am.* 1999;26:39–51.
7. Serden SP, Brooks PG. Treatment of abnormal uterine bleeding with the gynecologic resectoscope. *J Reprod Med.* 1991;36:697–699.
8. Munro MG. Medical management of abnormal uterine bleeding. *Obstet Gynecol Clin N Am.* 2000;27:287–304.
9. Boyd GL, Diethelm AG, Gelman S, et al. Correcting prolonged bleeding during renal transplantation with estrogen or plasma. *Arch Surg.* 1996; 131:160–165.
10. Homer HA, Li TC, Cooke ID. The septate uterus: a review of management and reproductive outcome. *Fertil Steril.* 2000;73:1–14.
11. Heinonen PK. Complete septate uterus with longitudinal vaginal septum. *Fertil Steril.* 2006;85:700–705.
12. Fedele L, Arcaini L, Parazzini F, et al. Reproductive prognosis after hysteroscopic metroplasty in 102 women: life-table analysis. *Fertil Steril.* 1993;59:768–772.
13. Mollo A, De Franciscis P, Colacurci N, et al. Hysteroscopic resection of the septum improves the pregnancy rate of women with unexplained infertility: a prospective controlled trial. *Fertil Steril.* 2009;91: 2628–2631.
14. Pabuccu R, Gomel V. Reproductive outcome after hysteroscopic metroplasty in women with septate uterus and otherwise unexplained infertility. *Fertil Steril.* 2004;81:1675–1678.
15. Shirota K, Fukuoka M, Tsujioka H, et al. A normal uterus communicating with a double cervix and the vagina: a mullerian anomaly without any present classification. *Fertil Steril.* 2009;91(935):e1–e3.
16. Saravelos SH, Cocksedge KA, Li TC. Prevalence and diagnosis of congenital uterine anomalies in women with reproductive failure: a critical appraisal. *Hum Reprod Update.* 2008;14:415–429.
17. DeVore GR, Owens O, Kase N. Use of intravenous Premarin in the treatment of dysfunctional uterine bleeding—a double-blind randomized control study. *Obstet Gynecol.* 1982;59:285–291.
18. Zreik TG, Odunsi K, Cass I, et al. A case of fatal pulmonary thromboembolism associated with the use of intravenous estrogen therapy. *Fertil Steril.* 1999;71:373–375.
19. McCall RE, Bilderback KK. Use of intravenous Premarin to decrease postoperative blood loss after pediatric scoliosis surgery. *Spine.* 1997; 22:1394–1397.
20. Frenette L, Cox J, McArdle P, et al. Conjugated estrogen reduces transfusion and coagulation factor requirements in orthotopic liver transplantation. *Anesth Analg.* 1998;86:1183–1186.
21. Rabbani LE, Seminario NA, Sciacca RR, et al. Oral conjugated equine estrogen increases plasma von Willebrand factor in postmenopausal women. *J Am Coll Cardiol.* 2002;40:1991–1999.
22. Heisteringer M, Stockenhuber F, Schneider B, et al. Effect of conjugated estrogens on platelet function and prostacyclin generation in CRF. *Kidney Int.* 1990;38:1181–1186.